

## Current Concepts

## DISSEMINATED INTRAVASCULAR COAGULATION

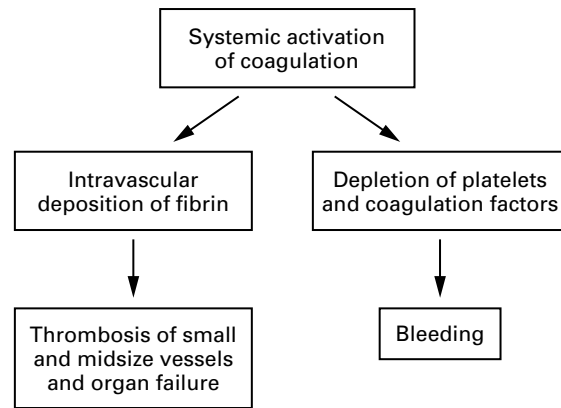
MARCEL LEVI, M.D., AND HUGO TEN CATE, M.D.

**D**ISSEMINATED intravascular coagulation is characterized by the widespread activation of coagulation, which results in the intravascular formation of fibrin and ultimately thrombotic occlusion of small and midsize vessels.<sup>1-3</sup> Intravascular coagulation can also compromise the blood supply to organs and, in conjunction with hemodynamic and metabolic derangements, may contribute to the failure of multiple organs. At the same time, the use and subsequent depletion of platelets and coagulation proteins resulting from the ongoing coagulation may induce severe bleeding (Fig. 1). Bleeding may be the presenting symptom in a patient with disseminated intravascular coagulation, a factor that can complicate decisions about treatment.

## ASSOCIATED CLINICAL CONDITIONS AND INCIDENCE

## Infectious Disease

Disseminated intravascular coagulation is an acquired disorder that occurs in a wide variety of clinical conditions, the most important of which are listed in Table 1. Infectious disease, in particular septicemia, is the most common clinical condition associated with disseminated intravascular coagulation. Although virtually all microorganisms can cause disseminated intravascular coagulation, bacterial infection is most frequently related to the development of the syndrome. Clinically overt disseminated intravascular coagulation may occur in 30 to 50 percent of patients with gram-negative sepsis.<sup>4,6</sup> Contrary to widely held belief, clinically overt disseminated intravascular coagulation appears to be as common in patients with gram-positive sepsis as in those with gram-negative sepsis.<sup>7</sup> Triggers of the activation of diffuse coagulation



**Figure 1.** The Mechanism of Disseminated Intravascular Coagulation.

Systemic activation of coagulation leads to widespread intravascular deposition of fibrin and depletion of platelets and coagulation factors. As a result, thrombosis of small and midsize vessels may occur, contributing to organ failure, and there may be severe bleeding.

**TABLE 1.** COMMON CLINICAL CONDITIONS ASSOCIATED WITH DISSEMINATED INTRAVASCULAR COAGULATION.

Sepsis
Trauma
Serious tissue injury
Head injury
Fat embolism
Cancer
Myeloproliferative diseases
Solid tumors (e.g., pancreatic carcinoma, prostatic carcinoma)
Obstetrical complications
Amniotic-fluid embolism
Abruptio placentae
Vascular disorders
Giant hemangioma (Kasabach–Merritt syndrome)
Aortic aneurysm
Reactions to toxins (e.g., snake venom, drugs, amphetamines)
Immunologic disorders
Severe allergic reaction
Hemolytic transfusion reaction
Transplant rejection

in patients with infections are cell-specific membrane components of the microorganism, such as lipopolysaccharide or endotoxin, or bacterial exotoxins (e.g., staphylococcal  $\alpha$  hemolysin). All these components may induce a generalized inflammatory response, characterized by the activation of the cytokine network.

From the Department of Vascular Medicine and Internal Medicine, Academic Medical Center, University of Amsterdam (M.L., H.C.), and the Department of Internal Medicine, Slotervaart Hospital (H.C.) — both in Amsterdam. Address reprint requests to Dr. Levi at the Department of Vascular Medicine and Internal Medicine, Academic Medical Centre F-4, Meibergdreef 9, 1105 AZ Amsterdam, the Netherlands, or at m.m.levi@amc.uva.nl. ©1999, Massachusetts Medical Society.

### Severe Trauma

Another clinical condition frequently associated with disseminated intravascular coagulation is severe trauma, particularly to the brain.<sup>1,6,8</sup> A combination of mechanisms, including the release of fat and phospholipids from tissue into the circulation, hemolysis, and endothelial damage, may promote the systemic activation of coagulation. In addition, there is emerging evidence that cytokines have a pivotal role in the development of disseminated intravascular coagulation, since the systemic activation patterns of cytokines are virtually identical in patients with polytrauma and patients with sepsis.<sup>9,10</sup> The incidence of disseminated intravascular coagulation among patients with severe trauma who have a systemic inflammatory response syndrome as a consequence is 50 to 70 percent.<sup>6,9</sup>

### Cancer

Both solid tumors and hematologic cancers may be complicated by disseminated intravascular coagulation. Ten to 15 percent of patients with metastasized tumors have evidence of disseminated intravascular coagulation, and the condition is present in approximately 15 percent of patients with acute leukemia.<sup>11,12</sup> The mechanism of the derangement of the coagulation system in patients with cancer is not clear. However, a number of studies indicate that tissue factor, which is expressed on the surface of tumor cells, is involved.<sup>13</sup> A distinct form of disseminated intravascular coagulation is frequently encountered in patients with acute promyelocytic leukemia, which is characterized by a severe hyperfibrinolytic state in addition to an activated coagulation system. Although bleeding is the most common clinical feature, disseminated thrombosis is found in some patients at autopsy.<sup>14</sup> Treatment with all-*trans*-retinoic acid, however, has drastically reduced the incidence of severe disseminated intravascular coagulation in patients with acute promyelocytic leukemia.

### Obstetrical Disorders

Disseminated intravascular coagulation is a classic complication of obstetrical conditions, such as abruptio placentae and amniotic-fluid embolism, occurring in more than 50 percent of patients with these conditions.<sup>15</sup> Leakage of thromboplastin-like material is likely to cause the systemic activation of coagulation, since amniotic fluid is a potent activator of coagulation in vitro and since the degree of placental separation correlates with the extent of disseminated intravascular coagulation. Although these obstetrical conditions may cause fulminant disseminated intravascular coagulation, the disorder is usually short-lived and self-limiting. Preeclampsia can also be complicated by disseminated intravascular coagulation, which occurred in 7 percent of consecutive patients with severe preeclampsia in one study.<sup>16</sup>

### Giant Hemangiomas

Giant hemangiomas (the Kasabach–Merritt syndrome) and even large aortic aneurysms may result in local activation of coagulation.<sup>17,18</sup> In patients with these conditions, local activation of coagulation most commonly results in the systemic depletion of locally consumed coagulation factors and platelets, but activated coagulation factors can reach the systemic circulation and cause disseminated intravascular coagulation. The incidence of clinically overt disseminated intravascular coagulation is 25 percent among patients with giant hemangiomas, whereas the incidence is approximately 0.5 to 1 percent among patients with large aortic aneurysms.<sup>18,19</sup>

### Microangiopathic Hemolytic Anemia

Microangiopathic hemolytic anemias comprise thrombocytopenic thrombotic purpura, the hemolytic–uremic syndrome, chemotherapy-induced microangiopathic hemolytic anemia, malignant hypertension, and the HELLP syndrome (hemolysis, elevated liver-enzyme levels, and a low platelet count occurring in association with preeclampsia).<sup>20</sup> Although some characteristics of microangiopathic hemolytic anemias and the resulting thrombotic occlusion of small and midsize vessels may mimic the clinical picture of disseminated intravascular coagulation, these disorders are a distinct group of diseases. The common feature of the microangiopathic hemolytic anemias appears to be endothelial damage, which causes the adhesion and aggregation of platelets, the formation of thrombin, and the impairment of fibrinolysis. In patients with thrombocytopenic thrombotic purpura and the hemolytic–uremic syndrome, the acquired deficiency of a protease that cleaves multimers of von Willebrand factor leads to the accumulation of large multimers of this factor.<sup>21</sup> A cardinal sign of microangiopathic hemolytic anemia is the presence of fragmented red cells (schistocytes) in the blood smear. Although hemolytic anemia and schistocytes are also sometimes present in patients with severe disseminated intravascular coagulation (because of the presence of intravascular fibrin), these are invariable findings in patients with microangiopathic hemolytic anemia.

### CLINICAL RELEVANCE AND PROGNOSIS

The contribution of disseminated intravascular coagulation to morbidity and the risk of mortality varies depending on the underlying clinical condition and the intensity of the coagulation disorder. Obviously, the seriousness of a severe depletion of platelets and coagulation factors in patients with diffuse and ongoing bleeding or in patients at high risk for bleeding (e.g., patients recovering from surgery) is indisputable. In addition, several lines of evidence indicate that disseminated intravascular coagulation increases the risk of organ failure and death. First,

histologic studies have shown that signs of ischemia and necrosis are related to the deposition of fibrin in the vasculature of organs in patients with disseminated intravascular coagulation.<sup>22</sup> Second, the amelioration of experimentally induced disseminated intravascular coagulation in animals decreases the risk of organ failure and, in some cases, death.<sup>23,24</sup> In a large number of clinical studies, the occurrence of disseminated intravascular coagulation appeared to be associated with an unfavorable outcome and was an independent predictor of mortality. Prospective clinical studies have shown that the development of disseminated intravascular coagulation in patients with sepsis or severe trauma roughly doubles the risk of death.<sup>6,10,25</sup> In spite of the apparent association between disseminated intravascular coagulation and the risk of death, however, it remains uncertain to what extent intravascular fibrin or coagulation proteases are the critical factors in determining the clinical course, rather than just the consequences of a more severe systemic inflammatory response.

### PATHOGENESIS

Recent studies in patients with disseminated intravascular coagulation and in animal models have largely clarified the pathogenetic pathways of the disorder. The systemic formation of fibrin results from increased generation of thrombin, the simultaneous suppression of physiologic anticoagulation mechanisms, and the delayed removal of fibrin as a consequence of impaired fibrinolysis (Fig. 2).

As is true for almost all systemic inflammatory responses, the derangement of coagulation and fibrinolysis in disseminated intravascular coagulation is mediated by several proinflammatory cytokines.<sup>26,27</sup> The principal mediator of the activation of coagulation appears to be interleukin-6. Tumor necrosis factor  $\alpha$  indirectly influences the activation of coagulation because of its effects on interleukin-6, and it is the pivotal mediator of the dysregulation of the physiologic anticoagulation pathways and the fibrinolytic defect.

#### Generation of Thrombin

Systemic generation of thrombin in animal models of disseminated intravascular coagulation was shown to be mediated exclusively by the extrinsic pathway involving tissue factor and activated factor VIIa. Inhibition of tissue factor or factor VIIa totally suppressed the endotoxin-induced generation of thrombin, whereas interference in the intrinsic pathway of coagulation did not affect the activation of coagulation.<sup>28-30</sup> The exact source of tissue factor is not always clear. Tissue factor may be expressed on mononuclear cells in response to proinflammatory cytokines,<sup>31</sup> but the role of the expression of tissue factor on vascular endothelial cells in disseminated intravascular coagulation remains to be elucidated.

#### Defects in Inhibitors of Coagulation

All major physiologic anticoagulants — antithrombin III, protein C, and tissue factor–pathway inhibitor — appear to be affected in patients with disseminated intravascular coagulation. Plasma levels of antithrombin III, the most important inhibitor of thrombin, are markedly reduced as a result of the ongoing coagulation, degradation by elastase released from activated neutrophils, and impaired synthesis of antithrombin III.<sup>24,32</sup>

A marked impairment of the protein-C system may further compromise the regulation of activated coagulation. This reduction in the activity of the protein-C system is caused by a combination of impaired protein synthesis, a cytokine-mediated decrease in the activity of endothelial thrombomodulin, and a decline in the level of the free fraction of protein S (the essential cofactor of protein C).<sup>33,34</sup>

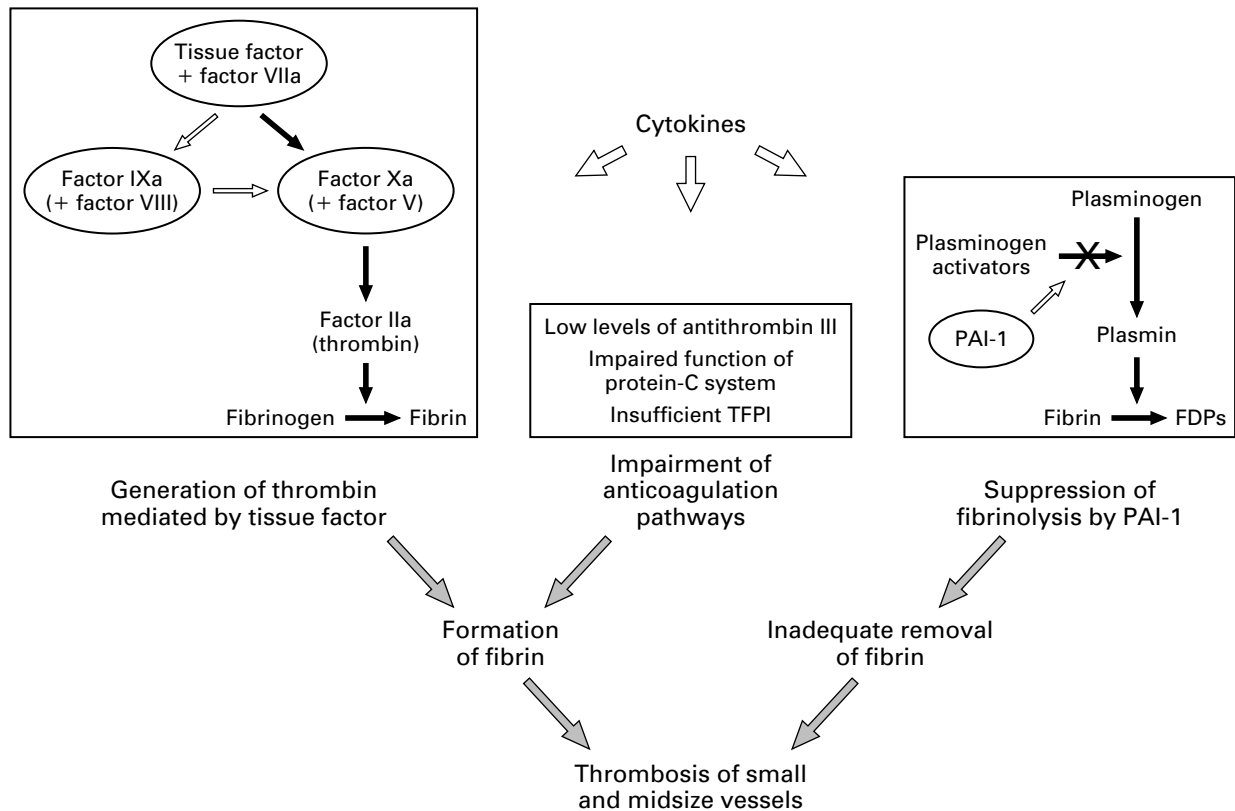
Tissue factor, the trigger of coagulation in disseminated intravascular coagulation, is inhibited by tissue factor–pathway inhibitor. Although no acquired deficiency or functional defect of tissue factor–pathway inhibitor has been identified in patients with disseminated intravascular coagulation, there is evidence that the inhibitor does not regulate tissue factor activity sufficiently in such patients.<sup>23</sup>

#### Fibrinolytic Defect

Studies in animal models of disseminated intravascular coagulation indicate that the fibrinolytic system is largely suppressed at the time of maximal activation of coagulation. This inhibition is caused by a sustained increase in the plasma level of plasminogen-activator inhibitor type 1, the principal inhibitor of the fibrinolytic system.<sup>28,35</sup> Clinical studies have confirmed that suppression of fibrinolysis is mediated by plasminogen-activator inhibitor type 1 and show that although there is some fibrinolytic activity in response to the formation of fibrin, the level of this activity is too low to counteract the systemic deposition of fibrin.<sup>6,10,36</sup>

### DIAGNOSIS

There is no single laboratory test that can establish or rule out the diagnosis of disseminated intravascular coagulation. However, a combination of test results in a patient with a clinical condition known to be associated with disseminated intravascular coagulation can be used to diagnose the disorder with reasonable certainty in most cases.<sup>37</sup> In clinical practice the disorder can be diagnosed on the basis of the following findings: an underlying disease known to be associated with disseminated intravascular coagulation; an initial platelet count of less than 100,000 per cubic millimeter or a rapid decline in the platelet count; prolongation of clotting times, such as the prothrombin time and the activated partial-thromboplastin time; the presence of fibrin-degradation



**Figure 2.** Pathogenetic Pathways Involved in Disseminated Intravascular Coagulation.

In patients with disseminated intravascular coagulation, fibrin is formed as a result of the generation of thrombin mediated by tissue factor. Tissue factor, expressed on the surface of activated mononuclear cells and endothelial cells, binds and activates factor VII. The complex of tissue factor and factor VIIa can activate factor X directly (black arrows) or indirectly (white arrows) by means of activated factor IX and factor VIII. Activated factor X, in combination with factor V, can convert prothrombin (factor II) to thrombin (factor IIa). Simultaneously, all three physiologic means of anticoagulation — antithrombin III, protein C, and tissue factor–pathway inhibitor (TFPI) — are impaired. The resulting intravascular formation of fibrin is not balanced by adequate removal of fibrin because endogenous fibrinolysis is suppressed by high plasma levels of plasminogen-activator inhibitor type 1 (PAI-1). The high levels of PAI-1 inhibit plasminogen-activator activity and consequently reduce the rate of formation of plasmin. The combination of increased formation of fibrin and inadequate removal of fibrin results in disseminated intravascular thrombosis. FDPs denotes fibrin-degradation products.

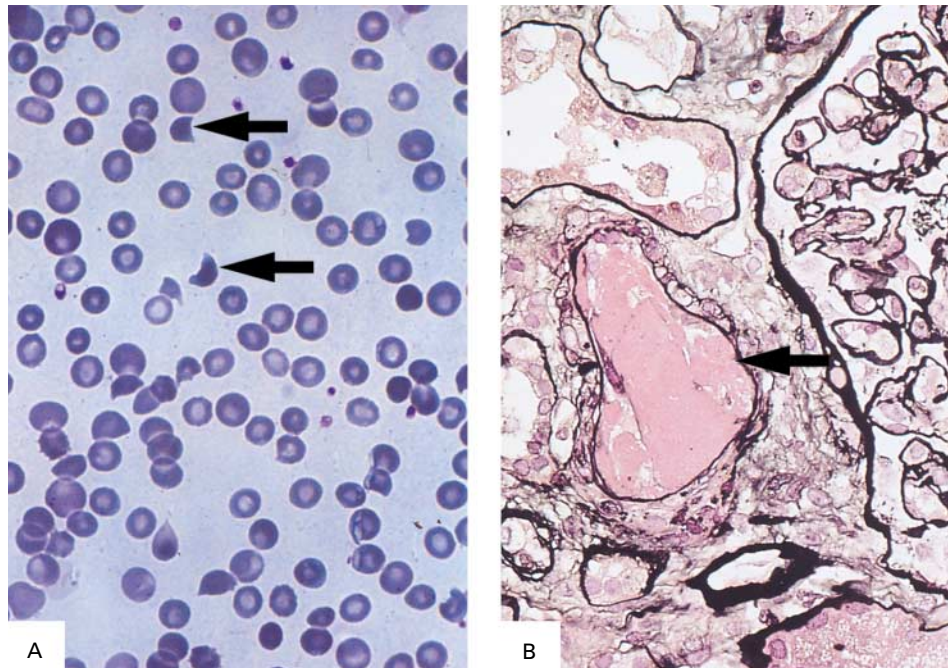
products in plasma; and low plasma levels of coagulation inhibitors, such as antithrombin III.

A low initial platelet count and, particularly, a progressive drop in the platelet count are sensitive, though not specific, signs of disseminated intravascular coagulation and may indicate ongoing thrombin-induced activation and use of platelets. Prolonged clotting times may reflect the depletion of coagulation factors, a possibility that can be substantiated by the measurement of one or two selected coagulation factors. Measurements of plasma coagulation factors may reveal other coagulation abnormalities, such as a deficiency of vitamin K.

Measurement of plasma fibrinogen has often been advocated, but plasma fibrinogen levels may remain in the normal range despite considerable coagulation activity, because this protein is an acute-phase react-

ant. In fact, clinical studies have shown that a finding of hypofibrinogenemia is useful diagnostically only in very severe cases of disseminated intravascular coagulation. Measurement of selected inhibitors of coagulation, including antithrombin III or protein C, may provide useful prognostic information.<sup>25,32</sup> Tests for fibrin-degradation products or D-dimers may be helpful to differentiate disseminated intravascular coagulation from other conditions that are associated with a low platelet count or prolonged clotting times.<sup>38</sup>

It may be difficult to differentiate between severe liver disease and disseminated intravascular coagulation, since the two disorders have the same characteristic laboratory abnormalities. Circumstantial findings such as portal hypertension, which is indicative of liver disease, or an underlying condition known to be associated with disseminated intravascular coagula-



**Figure 3.** Blood Smear (Panel A) and Kidney-Biopsy Specimen (Panel B) from a Patient with Disseminated Intravascular Coagulation.

In Panel A, the arrows indicate typical fragmented red cells (schistocytes). In Panel B, intravascular fibrin is present in a small arteriole (arrow). Courtesy of Jan J. Weening, M.D., Amsterdam. (Panel A: hematoxylin and eosin,  $\times 500$ ; Panel B: Jones methenamine silver,  $\times 300$ .)

tion may help in differentiating the two disorders. Also, the coagulation abnormalities resulting from uncomplicated liver disease usually tend to be stable rather than to worsen progressively. In patients with disseminated intravascular coagulation, the blood smear may contain schistocytes, and histologic analysis of organ-biopsy tissue may reveal the deposition of fibrin in small or midsize vessels (Fig. 3).

More specialized, but not generally available, laboratory tests that are useful in the diagnosis of disseminated intravascular coagulation include the measurement of soluble fibrin and sensitive assays that can measure the generation of thrombin, such as assays for the detection of prothrombin activation fragment  $F_{1+2}$  or thrombin-antithrombin complexes.<sup>39,40</sup> The sensitivity and specificity of these assays for the diagnosis of disseminated intravascular coagulation range from 80 to 90 percent, but although they may be helpful in complicated clinical situations, they are usually not essential in general clinical practice.

#### MANAGEMENT

The cornerstone of the management of disseminated intravascular coagulation is the treatment of the underlying disorder. Treatment of disseminated intravascular coagulation without treatment of the

underlying cause is predestined to fail. Supportive measures may be necessary, although firm evidence on which to base management is scarce, and there is no consensus regarding the optimal treatment or supportive strategy. A patient with disseminated intravascular coagulation who has diffuse bleeding from various sites at presentation will need different supportive treatment from what is appropriate for a patient with thrombotic obstruction of the vasculature and subsequent multiorgan failure.

#### Anticoagulants

Theoretically, interruption of coagulation should be of benefit in patients with disseminated intravascular coagulation. Indeed, experimental studies have shown that heparin can partially inhibit the activation of coagulation in cases that are related to sepsis or other causes. Adequate prophylaxis is also needed to eliminate the risk of venous thromboembolism. Heparin has been shown to have a beneficial effect in small, uncontrolled studies of patients with disseminated intravascular coagulation, but not in controlled clinical trials.<sup>41,42</sup> Although the safety of heparin in patients with disseminated intravascular coagulation who are prone to bleeding has often been debated, clinical studies have not shown that treatment with

heparin significantly increased the incidence of bleeding complications. Taken together, these findings suggest that treatment with heparin is probably useful in patients with disseminated intravascular coagulation, particularly those with clinically overt thrombocytopenia or extensive deposition of fibrin, as occurs with purpura fulminans or acral ischemia. Patients with disseminated intravascular coagulation are usually given relatively low doses of heparin (300 to 500 U per hour) as a continuous infusion. Low-molecular-weight heparin may also be used as an alternative to unfractionated heparin.<sup>43</sup>

Novel, antithrombin III-independent inhibitors of thrombin, such as desirudin and related compounds, might be more effective than heparin, and experimental studies have had promising results. However, there have not yet been any controlled clinical trials of these drugs in patients with disseminated intravascular coagulation, and the relatively high risk of bleeding associated with the use of these compounds may be a limiting factor.

#### Platelets and Plasma

Low levels of platelets and coagulation factors may cause serious bleeding or may increase the risk of bleeding in patients who require an invasive procedure. In such patients, the efficacy of treatment with platelet concentrate and plasma has clearly been shown.<sup>11,44</sup> There is no evidence to support the use of prophylactic administration of platelets or plasma to patients with disseminated intravascular coagulation who are not bleeding and who are not at high risk for bleeding. It may be necessary to administer large volumes of plasma (up to 6 units per 24 hours) to ameliorate or correct the coagulation defect. Treatment with coagulation-factor concentrates may overcome the need for large infusions of plasma, but their use in patients with disseminated intravascular coagulation is generally not advocated because the concentrates may be contaminated with traces of activated coagulation factors, which could exacerbate the coagulation disorder. Also, these concentrates contain only selected coagulation factors, whereas patients with disseminated intravascular coagulation usually have a deficiency of all coagulation factors.

#### Concentrates of Coagulation Inhibitors

Restoration of physiologic pathways of anticoagulation might be an appropriate aim of therapy. Antithrombin III is one of the most important natural inhibitors of coagulation, and patients with disseminated intravascular coagulation almost invariably have an acquired deficiency of antithrombin. The administration of this inhibitor in supraphysiologic concentrations reduced sepsis-related mortality in animals.<sup>24</sup> Several controlled clinical trials, mostly in patients with sepsis or with septic shock, have shown beneficial effects in terms of improvement of disseminated

intravascular coagulation and sometimes improvement in organ function.<sup>45-47</sup> In the more recent trials, very high doses of antithrombin III concentrate were used (up to 150 percent of normal), and the favorable effect in these trials seems to be more distinct. Some trials showed a modest reduction in mortality in patients treated with antithrombin III, but this effect did not reach statistical significance.

A meta-analysis of the trials with adequate study methods showed a reduction in mortality from 56 percent to 44 percent (odds ratio for death, 0.63; 95 percent confidence interval, 0.39 to 1.0).<sup>48</sup> At present, a large randomized, controlled multicenter trial with supraphysiologic dosing of antithrombin III in patients with sepsis is being conducted and the outcome of this trial will help determine the place of antithrombin III treatment in sepsis and disseminated intravascular coagulation. In the meantime, antithrombin III treatment may be considered as a supportive therapeutic option in patients with severe disseminated intravascular coagulation, although the substantial costs of this treatment may be a limiting factor.

#### Antifibrinolytic Agents

Antifibrinolytic treatment is effective in patients with bleeding, but the use of these agents in patients with disseminated intravascular coagulation is generally not recommended. Since the deposition of fibrin in this disorder appears to be due in part to insufficient fibrinolysis, further inhibition of the fibrinolytic system would not seem to be appropriate. A clear exception might be made in the case of patients with primary or secondary hyperfibrinolysis, such as those with the coagulopathy associated with acute promyelocytic leukemia and some patients with disseminated intravascular coagulation in association with cancer. In such patients, antifibrinolytic treatment has controlled the coagulopathy.<sup>49</sup>

#### FUTURE THERAPEUTIC OPTIONS

A logical therapeutic intervention would be directed against tissue-factor activity. One such inhibitor, recombinant nematode anticoagulant protein c2, a potent and specific inhibitor of the complex formed by tissue factor and factor VIIa with factor Xa, has recently been developed and is currently being evaluated in a clinical study.<sup>50</sup> Administration of recombinant tissue factor-pathway inhibitor may also block tissue-factor activity in endotoxin-induced activation of coagulation (de Jonge E, et al.: unpublished data). This possibility is now being evaluated in clinical trials.

In view of the impairment of the protein-C system in patients with disseminated intravascular coagulation, supplementation with (activated) protein C may be beneficial,<sup>51</sup> as was true in an animal model of the disorder.<sup>52</sup> Adequately controlled clinical trials of protein-C concentrates are currently being initiated or are under way.

Dr. Levi is an Investigator of the Royal Dutch Academy of Arts and Sciences. Dr. ten Cate is a Clinical Established Investigator of the Netherlands Heart Foundation.

## REFERENCES

- Marder VJ, Feinstein DI, Francis CW, Colman RW. Consumptive thrombohemorrhagic disorders. In: Colman RW, Hirsh J, Marder VJ, Salzman EW, eds. Hemostasis and thrombosis: basic principles and clinical practice. 3rd ed. Philadelphia: J.B. Lippincott, 1994:1023-63.
- Bone RC. Modulators of coagulation: a critical appraisal of their role in sepsis. *Arch Intern Med* 1992;152:1381-9.
- Müller-Berghaus G, ten Cate H, Levi MM. Disseminated intravascular coagulation. In: Verstraete M, Fuster V, Topol EJ, eds. Cardiovascular thrombosis: thrombocardiology and thrombonerology. 2nd ed. Philadelphia: Lippincott-Raven, 1998:781-801.
- Thijs LG, de Boer JP, de Groot MCM, Hack CE. Coagulation disorders in septic shock. *Intensive Care Med* 1993;19:Suppl 1:S8-S15.
- Baglin T. Disseminated intravascular coagulation: diagnosis and treatment. *BMJ* 1996;312:683-7.
- Gando S, Kameue T, Nanzaki S, Nakanishi Y. Disseminated intravascular coagulation is a frequent complication of systemic inflammatory response syndrome. *Thromb Haemost* 1996;75:224-8.
- Bone RC. Gram-positive organisms and sepsis. *Arch Intern Med* 1994;154:26-34.
- Hulka F, Mullins RJ, Frank EH. Blunt brain injury activates the coagulation process. *Arch Surg* 1996;131:923-8.
- Roumen RMH, Hendriks T, van der Ven-Jongekrijg J, et al. Cytokine patterns in patients after major vascular surgery, hemorrhagic shock, and severe blunt trauma: relation with subsequent adult respiratory distress syndrome and multiple organ failure. *Ann Surg* 1993;6:769-76.
- Gando S, Nakanishi Y, Tedo I. Cytokines and plasminogen activator inhibitor-1 in posttrauma disseminated intravascular coagulation: relationship to multiple organ dysfunction syndrome. *Crit Care Med* 1995;23:1835-42.
- Colman RW, Rubin RN. Disseminated intravascular coagulation due to malignancy. *Semin Oncol* 1990;17:172-86.
- Sarris AH, Kempin S, Berman E, et al. High incidence of disseminated intravascular coagulation during remission induction of adult patients with acute lymphoblastic leukemia. *Blood* 1992;79:1305-10.
- Contrino J, Hair G, Kreutzer DL, Rickles FR. In situ detection of expression of tissue factor in vascular endothelial cells: correlation with the malignant phenotype of human breast disease. *Nat Med* 1996;2:209-15.
- Falanga A, Consonni R, Marchetti M, et al. Cancer procoagulant and tissue factor are differentially modulated by all-trans-retinoic acid in acute promyelocytic leukemia cells. *Blood* 1998;92:143-51.
- Weiner CP. The obstetric patient and disseminated intravascular coagulation. *Clin Perinatol* 1986;13:705-17.
- Sibai BM, Spinnato JA, Watson DL, Hill GA, Anderson GD. Pregnancy outcome in 303 cases with severe preeclampsia. *Obstet Gynecol* 1984;64:319-25.
- Szlachetka DM. Kasabach-Merritt syndrome: a case review. *Neonatal Netw* 1998;17(1):7-15. [Erratum, *Neonatal Netw* 1998;17(3):21.]
- Aboulaia DM, Aboulaia ED. Aortic aneurysm-induced disseminated intravascular coagulation. *Ann Vasc Surg* 1996;10:396-405.
- Kazmers A, Jacobs L, Perkins A, Lindenauer SM, Bates E. Abdominal aortic aneurysm repair in Veterans Affairs medical centers. *J Vasc Surg* 1996;23:191-200.
- Ruggenti P, Lutz J, Remuzzi G. Pathogenesis and treatment of thrombotic microangiopathy. *Kidney Int Suppl* 1997;58:S97-S101.
- Furlan M, Robles R, Galbusera M, et al. Von Willebrand factor—cleaving protease in thrombotic thrombocytopenic purpura and the hemolytic-uremic syndrome. *N Engl J Med* 1998;339:1578-84.
- Regoczi E, Brain MC. Organ distribution of fibrin in disseminated intravascular coagulation. *Br J Haematol* 1969;17:73-81.
- Creasey AA, Chang ACK, Feigen L, Wun TC, Taylor FB Jr, Hinshaw LB. Tissue factor pathway inhibitor reduces mortality from *Escherichia coli* septic shock. *J Clin Invest* 1993;91:2850-6.
- Kessler CM, Tang Z, Jacobs HM, Szymanski LM. The suprapharmacological dosing of antithrombin concentrate for *Staphylococcus aureus*-induced disseminated intravascular coagulation in guinea pigs: substantial reduction in mortality and morbidity. *Blood* 1997;89:4393-401.
- Fourrier F, Chopin C, Goudehand J, et al. Septic shock, multiple organ failure, and disseminated intravascular coagulation: compared patterns of antithrombin III, protein C, and protein S deficiencies. *Chest* 1992;101:816-23.
- van der Poll T, Büller HR, ten Cate H, et al. Activation of coagulation after administration of tumor necrosis factor to normal subjects. *N Engl J Med* 1990;322:1622-7.
- Levi M, van der Poll T, ten Cate H, van Deventer SJH. The cytokine-mediated imbalance between coagulant and anticoagulant mechanisms in sepsis and endotoxemia. *Eur J Clin Invest* 1997;27:3-9.
- Levi M, ten Cate H, Bauer KA, et al. Inhibition of endotoxin-induced activation of coagulation and fibrinolysis by pentoxifylline or by a monoclonal anti-tissue factor antibody in chimpanzees. *J Clin Invest* 1994;93:114-20.
- Taylor FB Jr, Chang A, Ruf W, et al. Lethal *E. coli* septic shock is prevented by blocking tissue factor with monoclonal antibody. *Circ Shock* 1991;33:127-34.
- Pixley RA, De La Cadena R, Page JD, et al. The contract system contributes to hypotension but not disseminated intravascular coagulation in lethal bacteremia: in vivo use of a monoclonal anti-factor XII antibody to block contact activation in baboons. *J Clin Invest* 1993;92:61-8.
- Østerud B, Flaegstad T. Increased tissue thromboplastin activity in monocytes of patients with meningococcal infection: related to an unfavourable prognosis. *Thromb Haemost* 1983;49:5-7.
- Mesters RM, Mannucci PM, Coppola R, Keller T, Ostermann H, Kleinast J. Factor VIIa and antithrombin III activity during severe sepsis and septic shock in neutropenic patients. *Blood* 1996;88:881-6.
- Conway EM, Rosenberg RD. Tumor necrosis factor suppresses transcription of the thrombomodulin gene in endothelial cells. *Mol Cell Biol* 1988;8:5588-92.
- Taylor FB, Chang A, Ferrell G, et al. C4b-binding protein exacerbates the host response to *Escherichia coli*. *Blood* 1991;78:357-63.
- Suffredini AF, Harpel PC, Parrillo JE. Promotion and subsequent inhibition of plasminogen activator after administration of intravenous endotoxin to normal subjects. *N Engl J Med* 1989;320:1165-72.
- Nossel HL. Relative proteolysis of the fibrinogen B7 chain by thrombin and plasmin as a determinant of thrombosis. *Nature* 1981;291:165-7.
- Bick RL. Disseminated intravascular coagulation: objective clinical and laboratory diagnosis, treatment, and assessment of therapeutic response. *Semin Thromb Hemost* 1996;22:69-88.
- Bick RL, Baker WF. Diagnostic efficacy of the D-dimer assay in disseminated intravascular coagulation (DIC). *Thromb Res* 1992;65:785-90.
- Wada H, Wakita Y, Nakase T, et al. Increased plasma-soluble fibrin monomer levels in patients with disseminated intravascular coagulation. *Am J Hematol* 1996;51:255-60.
- Bauer KA, Rosenberg RD. The pathophysiology of the prethrombotic state in humans: insights gained from studies using markers of hemostatic system activation. *Blood* 1987;70:343-50.
- Corrigan JJ Jr. Heparin therapy in bacterial septicemia. *J Pediatr* 1977;91:695-700.
- Feinstein DI. Diagnosis and management of disseminated intravascular coagulation: the role of heparin therapy. *Blood* 1982;60:284-7.
- Sakuragawa N, Hasegawa H, Maki M, Nakagawa M, Nakashima M. Clinical evaluation of low-molecular-weight heparin (FR-860) on disseminated intravascular coagulation (DIC) — a multicenter co-operative double-blind trial in comparison with heparin. *Thromb Res* 1993;72:475-500.
- Feinstein DI. Treatment of disseminated intravascular coagulation. *Semin Thromb Hemost* 1988;14:351-62.
- Fourrier F, Chopin C, Huart JJ, Runge I, Caron C, Goudehand J. Double-blind, placebo-controlled trial of antithrombin III concentrates in septic shock with disseminated intravascular coagulation. *Chest* 1993;104:882-8.
- Baudo F, Caimi TM, de Cataldo F, et al. Antithrombin III (ATIII) replacement therapy in patients with sepsis and/or postsurgical complications: a controlled double-blind, randomized, multicenter study. *Intensive Care Med* 1998;24:336-42.
- Eisele B, Lamy M, Thijs LG, et al. Antithrombin III in patients with severe sepsis: a randomized placebo-controlled, double-blind multicenter trial plus meta-analysis on all randomized, placebo-controlled, double-blind trials with antithrombin III in severe sepsis. *Intensive Care Med* 1998;24:663-72.
- Levi M, de Jonge E, van der Poll T, ten Cate H. Disseminated intravascular coagulation: state of the art 1999. *Thromb Haemost* (in press).
- Avvisati G, ten Cate JW, Buller HR, Mandelli F. Tranexamic acid for control of haemorrhage in acute promyelocytic leukaemia. *Lancet* 1989;2:122-4.
- Bergum P, Cruikshank A, Maki S, Ruf W, Vlasuk G. The potent, factor X(a)-dependent inhibition by rNAPc2 of factor VIIa (FVIIa)/tissue factor involves the binding of its cofactor to a exosite on FVII, followed by occupation of the active site. *Blood* 1998;92:Suppl 1:669a. abstract.
- Smith OP, White B, Vaughan D, et al. Use of protein-C concentrate, heparin, and haemodiafiltration in meningococcus-induced purpura fulminans. *Lancet* 1997;350:1590-3.
- Taylor FB Jr, Chang A, Esmon CT, D'Angelo A, Viganò-D'Angelo S, Blick KE. Protein C prevents the coagulopathic and lethal effects of *Escherichia coli* infusion in the baboon. *J Clin Invest* 1987;79:918-25.