

## REVIEW ARTICLE

Dan L. Longo, M.D., *Editor*

## Spontaneous Coronary-Artery Dissection

Esther S.H. Kim, M.D., M.P.H.

From the Department of Medicine, Division of Cardiovascular Medicine, Vanderbilt University Medical Center, Nashville. Address reprint requests to Dr. Kim at the Department of Medicine, Division of Cardiovascular Medicine, Vanderbilt University Medical Center, 1215 21st Ave. S., Medical Center E., 5th Fl., South Tower, Nashville, TN 27232, or at [esther.kim@vumc.org](mailto:esther.kim@vumc.org).

N Engl J Med 2020;383:2358-70.

DOI: 10.1056/NEJMra2001524

Copyright © 2020 Massachusetts Medical Society.

**S**PONTANEOUS CORONARY-ARTERY DISSECTION (SCAD) HAS EMERGED AS an important cause of myocardial infarction in young persons. SCAD occurs primarily in women, and the prevalence of cardiovascular risk factors among women with myocardial infarction from SCAD is lower than the prevalence of risk factors among women with myocardial infarction from atherosclerosis.<sup>1-5</sup> Although SCAD is uncommon, awareness of both the disease and its angiographic appearance has improved.<sup>6</sup> Accurate and rapid diagnosis is paramount because the management of acute myocardial infarction caused by SCAD differs vastly from that of atherosclerotic myocardial infarction. SCAD can be a forme fruste of an underlying systemic arteriopathy<sup>7</sup> — namely, fibromuscular dysplasia.<sup>4,8,9</sup>

## PATHOPHYSIOLOGY

SCAD is defined as a separation of the layers of an epicardial coronary-artery wall by intramural hemorrhage, with or without an intimal tear. This condition is not associated with atherosclerosis, iatrogenic injury, or trauma.<sup>10-13</sup> Although one hypothesis posits that an intimal tear results in the creation and propagation of a false lumen within the medial layer,<sup>14,15</sup> the presence of a coronary intramural hematoma without evidence of an intimal tear was detected almost 20 years ago with the use of intravascular ultrasonography.<sup>16</sup> Higher-resolution optical coherence tomography (OCT) has provided even more support for the hypothesis that the primary event may be medial dissection or rupture of the vasa vasorum resulting in a secondary intramural hemorrhage and formation of an intramural hematoma.<sup>17</sup> The final common pathway for the development of acute myocardial infarction is coronary obstruction due to luminal compression, either by a dissection flap or by propagation of an intramural hematoma (Fig. 1).<sup>12</sup>

## EPIDEMIOLOGY

SCAD can affect both sexes across the life span, beginning in adolescence. However, approximately 90% of patients with this condition are women who present between 47 and 53 years of age.<sup>1,4,5,22</sup> The prevalence of typical cardiovascular risk factors is lower among these patients than among those who have a myocardial infarction from atherosclerotic disease.<sup>2,5</sup> Estimates derived from administrative data sets suggest that SCAD accounts for less than 1% of all acute myocardial infarctions.<sup>2,5,23</sup> In contrast, cohort studies incorporating direct angiographic review indicate that one quarter to one third of myocardial infarctions in women younger than 50 years of age are caused by SCAD,<sup>24,25</sup> and SCAD accounts for approximately 15 to 20% of myocardial infarctions during pregnancy or the peripartum period.<sup>26,27</sup> Thus, although SCAD remains an uncommon cause of myocardial infarction overall, its role in myocardial infarctions among women is considerable.

Data on SCAD in men are limited because the prevalence of this condition among men is low. Men with SCAD have a lower prevalence of anxiety and depression,<sup>3</sup> more often cite a physical stressor (e.g., exercise or heavy lifting) rather than an emotional stressor before symptom onset,<sup>3,28</sup> and tend to have a lower prevalence of fibromuscular dysplasia than women with SCAD.<sup>28</sup>


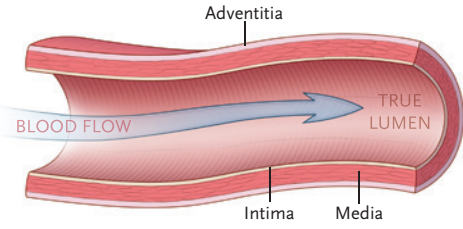
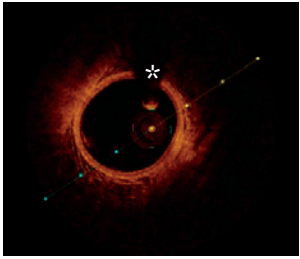
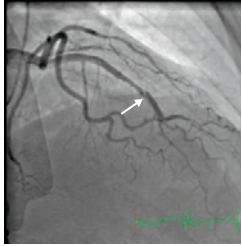
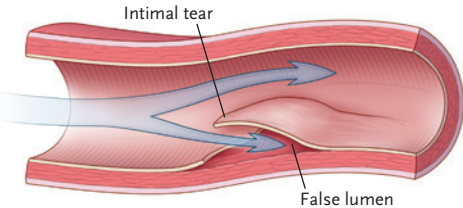
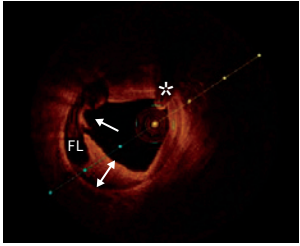
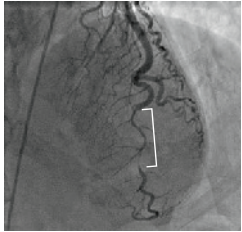
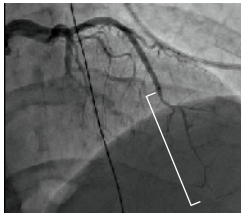
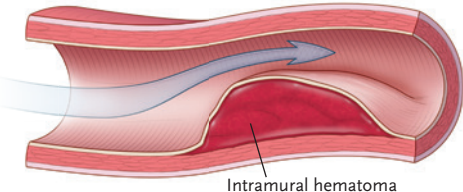
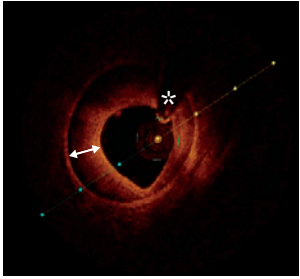
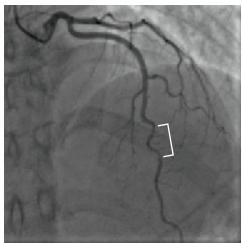
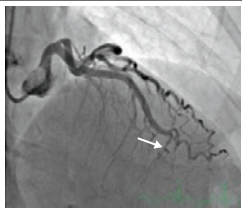
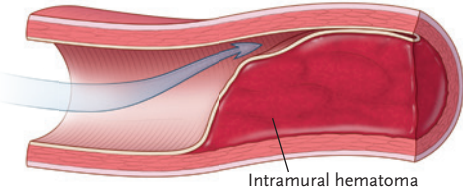
The cause of SCAD is unknown but probably includes factors related to patient vulnerabilities and inciting triggers such as emotional stress, physical stress (e.g., from an extreme Valsalva maneuver, retching, vomiting, coughing, or isometric exercise), the use of stimulant medications or illicit drugs, and hormonal triggers (e.g., pregnancy).<sup>8</sup> Numerous case reports describe an association between SCAD and several inflammatory disorders such as systemic lupus erythematosus, sarcoidosis, inflammatory bowel disease, and celiac disease; however, registry data indicate that the prevalence of systemic inflammatory disorders among patients with SCAD is low (<5% in most cohorts).<sup>1,4,9,22,29</sup> Pathological autopsy specimens have shown a focal infiltration of inflammatory cells, predominantly eosinophils, that is limited to the adventitia and periaortic soft tissue of the dissected epicardial coronary arteries.<sup>30,31</sup> Notably absent are inflammatory changes in the intima and media; this absence differentiates this condition from arteritides such as polyarteritis nodosa or eosinophilic granulomatosis with polyangiitis (formerly known as the Churg–Strauss syndrome), and the absence of granulomatous inflammation or vasculitis in other tissues or organs rules out systemic inflammatory diseases. Early postmortem case reports<sup>32</sup> described cystic medial necrosis of the coronary artery, but this finding has been absent in more recent autopsy reports.<sup>33-35</sup>

The predilection of SCAD to affect women disproportionately provides compelling fodder for a hypothesis of a role of hormones in this condition, but the percentage of postmenopausal women in SCAD registries is consistently approximately 55%,<sup>1,4,22,29</sup> and the prevalences of nulliparity and multiparity are similar among patients with SCAD.<sup>4</sup> Peripartum SCAD accounts for fewer than 15% of all cases,<sup>1,3-5,22</sup> but when SCAD does occur in the peripartum period, it is associated with an increased prevalence of left main and multivessel involvement, a decreased ejection fraction, and an increased prevalence of

ST-segment elevation myocardial infarction (STEMI).<sup>36-38</sup> Thus, although sex hormones may play a role in the pathogenesis of SCAD, the mechanism and magnitude of effect are unknown.

Familial cases of SCAD have been reported among first-degree and second-degree family members,<sup>39</sup> but most cases are sporadic, so it is unlikely to be a monogenic disease. Among patients with SCAD who are referred for panel-based sequencing of genes known to cause aortopathies or connective-tissue diseases (e.g., vascular Ehlers–Danlos syndrome, Marfan’s syndrome, and the Loeys–Dietz syndrome), the prevalence of a disease-causing mutation is approximately 5 to 8%.<sup>7,40</sup> In a recent study involving a multicenter cohort of unrelated patients with SCAD, the prevalence of rare variants in known thoracic aortic aneurysm and dissection genes was 10.6%, and there was a high frequency of variants associated with the Loeys–Dietz syndrome. This finding suggests a role for dysregulated transforming growth factor  $\beta$  signaling in the pathogenesis of SCAD. None of the patients in that study had clinical features that were typical of the Loeys–Dietz syndrome.<sup>41</sup> Currently, apart from genetic screening of first-degree family members of patients with SCAD in whom a monogenic vascular disease has been diagnosed, no firm recommendations are in place for routine genetic or clinical screening of asymptomatic relatives of patients after a SCAD event.<sup>13</sup> Recommendations based on expert consensus do exist for screening family members of patients with fibromuscular dysplasia, so relatives of patients with SCAD who also have fibromuscular dysplasia could be evaluated with clinical examination and imaging to detect fibromuscular dysplasia if they have signs or symptoms of that condition.<sup>42</sup>

*PHACTR1-EDN1*, a genetic locus known to be associated with migraine headache, cervical-artery dissection, and fibromuscular dysplasia, has also been shown to be associated with an increased risk of SCAD in multiple cohorts.<sup>43-45</sup> Several other susceptibility genes have been identified with the use of whole-exome sequencing in cases of familial and sporadic SCAD,<sup>46-49</sup> and genomewide association studies have identified additional susceptibility loci with variants within or near genes (*LRP1*, *LINC00310*, *FBN1*, and *ADAMTSL4*) that are expressed in arteries and that have been previously described in other ar-

Classification	Angiographic appearance	Anatomical appearance	Intravascular appearance on OCT
Normal coronary artery			
Type 1 SCAD			
Type 2A SCAD			
Type 2B SCAD			
Type 3 SCAD			
Type 4 SCAD			

**Figure 1 (facing page). Angiographic, Anatomical, and Intravascular Appearance of SCAD.**

A normal coronary artery appears as a smooth vessel, free of luminal irregularities. Asterisks indicate a guide-wire shadow artifact. Type 1 spontaneous coronary-artery dissection (SCAD) has the pathognomonic angiographic appearance of an arterial dissection, including multiple radiolucent lumens due to an intimal tear that causes contrast dye to penetrate through two flow channels. A radiolucent flap separating the two flow channels is visible on angiography (left image, arrow). Type 1 SCAD also can result in retention of contrast dye within the intimal tear or slow clearing of contrast material. On optical coherence tomography (OCT), an intimal tear (right image, arrow) separating the true lumen from the false lumen (FL) is shown. Double-headed arrows indicate an intramural hematoma. Type 2 SCAD is the most common type; 60 to 75% of patients with SCAD have this angiographic diagnosis.<sup>3,4</sup> Type 2 SCAD is characterized by the absence of an intimal tear and appears as a long segment of diffusely narrowed artery because of an intramural hematoma that causes stenosis of varying severity.<sup>18</sup> Type 2 SCAD lesions are long (typically >20 mm), often appear as an abrupt caliber change in the artery (angiographic images, square brackets), and will either be flanked by an artery of normal caliber (type 2A) or continue to the tip of the artery (type 2B). OCT imaging shows an intramural hematoma. The type 3 variant is the least common type of SCAD and the most challenging type to recognize on angiography. The appearance also suggests compression by an intramural hematoma, but type 3 SCAD is usually 20 mm or less in length. Type 3 SCAD is described as an atherosclerosis mimic,<sup>19</sup> and intracoronary imaging is often necessary to confirm the diagnosis. This type should be considered when there is a high index of suspicion for SCAD, atherosclerosis is absent in the remainder of the coronary vasculature, the lesion is linear and long (11 to 20 mm), or coronary tortuosity is present.<sup>20</sup> As with type 2 SCAD lesions, OCT imaging reveals a compressive intramural hematoma. Intracoronary nitroglycerin can be administered during angiography, particularly when type 2 or type 3 SCAD is suspected, to rule out the possibility that coronary vasospasm is causing the angiographic abnormality.<sup>12,19</sup> Finally, type 4 SCAD<sup>21</sup> has been described as a complete occlusion of the vessel (arrow). Its appearance may be similar to that of thromboembolic occlusion, and dissection as the cause of occlusion may be evident only when the underlying vessel architecture appears after vessel recanalization or after exclusion of an embolic cause and repeat coronary angiography shows healing of the vessel.<sup>12</sup> Repeat angiography that shows artery healing or the presence of extracoronary arterial findings provides support for the diagnosis of SCAD. OCT images are courtesy of Luis A.P. Dallan, M.D., Ph.D., on behalf of the Cardiovascular Imaging Core Laboratory, University Hospitals Cleveland Medical Center, Cleveland.

terial disorders.<sup>44,45</sup> A polygenic risk score for SCAD derived from genomewide association testing was associated with a decreased risk of atherosclerotic coronary artery disease.<sup>45</sup> Thus, taken together, these genetic studies formulate the basis for a thesis that myocardial infarction due to SCAD is a pathophysiological entity that is distinct from myocardial infarction due to atherosclerosis.

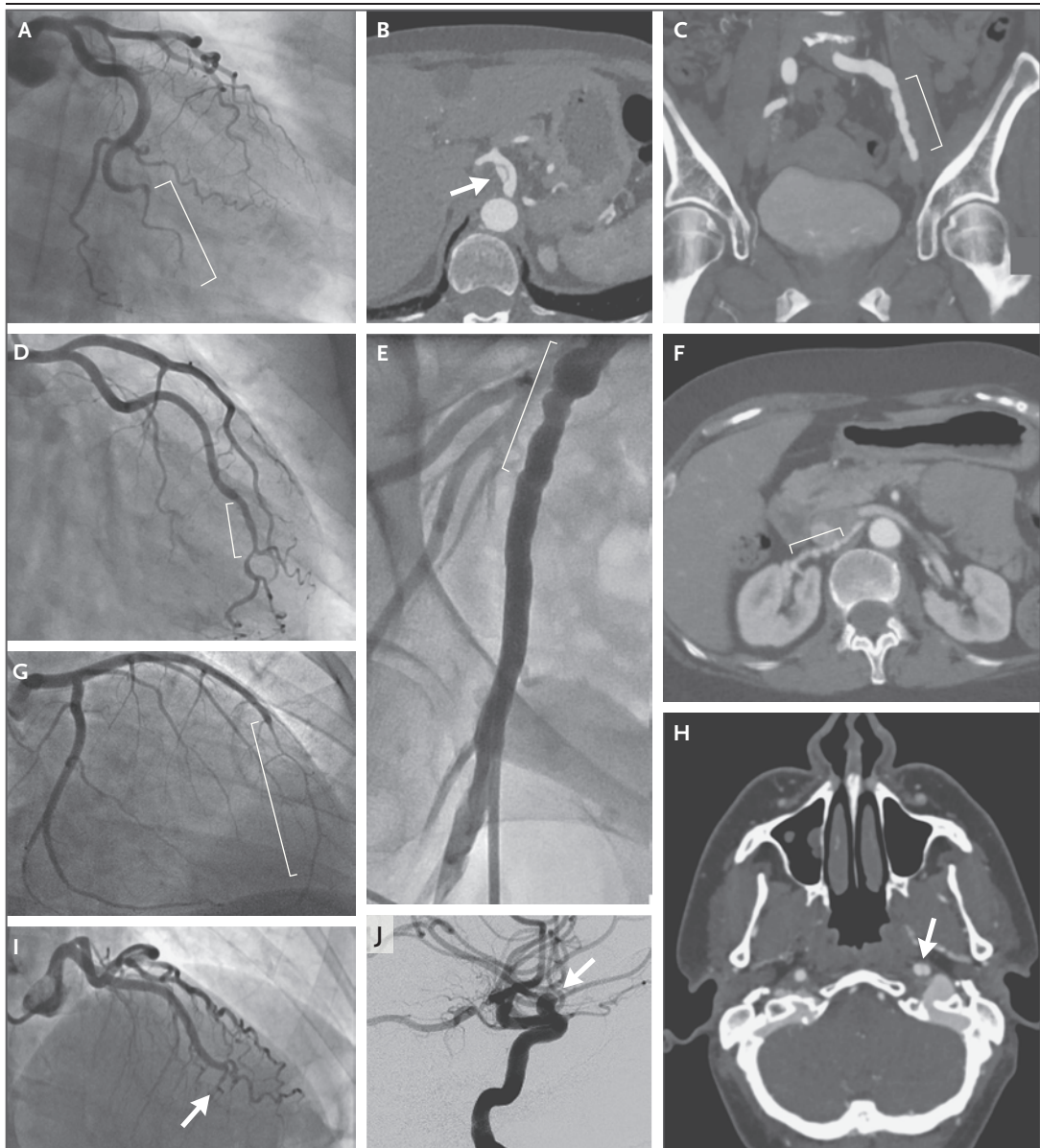
A consistent finding in registries of patients with SCAD is the high prevalence of concomitant noncoronary arterial abnormalities (Fig. 2). In the cohorts with the highest incidence of screening,<sup>9,29</sup> more than 50% of the patients also had fibromuscular dysplasia, and autopsy<sup>35,50,51</sup> and intracoronary imaging<sup>52</sup> studies suggest that SCAD may be an initial manifestation of fibromuscular dysplasia. Abnormalities known to be associated with fibromuscular dysplasia are cervical-artery, visceral-artery, and peripheral-artery aneurysm, as well as pseudoaneurysm, dissection, and tortuosity,<sup>42</sup> but these findings have also been reported in multiple cohorts of patients with SCAD, even in the absence of diagnosed concurrent fibromuscular dysplasia.<sup>9,20,22</sup> Cerebral aneurysm has been detected in 7 to 14% of patients with SCAD who have undergone screening.<sup>4,9,29</sup> Whether or not SCAD is a coronary manifestation of fibromuscular dysplasia or a unique but related entity with a considerable number of arterial features in common, it is clear that SCAD may be a *forme fruste* of an underlying systemic arteriopathy that leaves the affected patient vulnerable to dissection when exposed to arterial shear stress related to an inciting trigger.<sup>29</sup>

---

#### CLINICAL SIGNS AND SYMPTOMS

---

In more than 90% of patients who survive to initial evaluation, SCAD manifests as myocardial infarction.<sup>3,4,53</sup> Approximately 20 to 50% of patients present with STEMI,<sup>3,4,29,53,54</sup> approximately 3 to 5% present with ventricular arrhythmias for which cardioversion is warranted,<sup>4,29,53,55,56</sup> and 2% present in cardiogenic shock.<sup>53</sup> Chest pain, the chief symptom reported in 85 to 96% of patients, is variably associated with radiation of pain to the arm, neck, or back; dyspnea; and



diaphoresis.<sup>57,58</sup> A total of 25% of patients who present to the emergency department with an acute coronary syndrome report having had similar symptoms previously, but they did not seek medical care.<sup>58</sup> This phenomenon may account for the rare cases in which SCAD is diagnosed in patients who do not present with an acute myocardial infarction. Since 27% of initial troponin levels are reported as being normal in patients who ultimately receive a diagnosis of SCAD,<sup>58</sup> a heightened degree of suspicion for SCAD must be present to avoid missing the diagnosis.

#### DIAGNOSIS

SCAD is diagnosed with angiography. Patients in whom SCAD is the suspected cause of acute myocardial infarction should undergo coronary angiography<sup>13</sup> to confirm the diagnosis and define high-risk anatomical features that would warrant consideration of early revascularization. Early recognition is critical because there are important differences between the management of SCAD and the management of atherosclerotic acute myocardial infarction. Downstream cross-sectional imaging of the vasculature outside of

**Figure 2 (facing page). Extracoronary Vascular Abnormalities in SCAD.**

A 70-year-old woman with an acute myocardial infarction presented with ventricular fibrillation and SCAD of an obtuse marginal branch of the left circumflex artery (Panel A, bracket). Computed tomographic angiography (CTA) of the abdomen and pelvis revealed a celiac-artery dissection (Panel B, arrow) and multifocal fibromuscular dysplasia of the left external iliac artery (Panel C, bracket). A 57-year-old woman presented with non-ST-segment elevation myocardial infarction (STEMI) and SCAD of the obtuse marginal branch of the left circumflex artery (Panel D, bracket). Limited femoral angiography of the right external iliac artery at the completion of coronary angiography revealed mild aneurysmal changes and beading that were consistent with multifocal fibromuscular dysplasia (Panel E, bracket). CTA also showed fibromuscular dysplasia of the right renal artery (Panel F, bracket). A 35-year-old woman had SCAD of the left anterior descending artery (Panel G, bracket) 2 weeks after delivering her fourth child. She had had a left internal carotid artery dissection 10 years before SCAD, and CTA of the head and neck showed a dissection of the left internal carotid artery (Panel H, arrow) and multifocal fibromuscular dysplasia of the right internal carotid artery and bilateral vertebral arteries. A 47-year-old woman presented with STEMI and complete occlusion of the left anterior descending artery that was presumed to be caused by type 4 SCAD (Panel I, arrow). CTA (Panel J) showed fibromuscular dysplasia of the bilateral renal arteries, bilateral external iliac arteries, and bilateral cervical internal carotid and vertebral arteries, as well as a supraclinoid left internal carotid artery aneurysm measuring 6.5 mm (arrow).

the heart is indicated in patients with acute myocardial infarction due to SCAD,<sup>13</sup> and there may be clinically significant differences between SCAD and atherosclerotic acute myocardial infarction with respect to morbidity and mortality.<sup>2,5,23</sup>

SCAD is classified into distinct angiographic categories<sup>19</sup> that are primarily differentiated by the presence or absence of an intimal tear (Fig. 1). SCAD can occur in any coronary artery, but the left anterior descending artery and its branches are most commonly involved,<sup>3,59</sup> and multivessel SCAD involving noncontiguous arteries occurs in approximately 10 to 15% of patients with SCAD.<sup>4,29</sup> Although the majority of SCAD lesions can be diagnosed with angiography alone, it may be difficult to distinguish a potential case of SCAD from other causes of coronary-artery stenosis. In contrast to the approach for patients with myocardial infarction caused by atherosclerosis, the favored approach for patients with SCAD who are in clinically

stable condition is medical treatment.<sup>12,13</sup> Thus, when angiography is not diagnostic for SCAD, ancillary imaging techniques such as intravascular ultrasonography<sup>60</sup> or OCT<sup>61</sup> may be used for confirmation<sup>12,13</sup> (Fig. 1). Whereas angiography provides a “lumenogram” of the artery, intravascular imaging — particularly OCT, with its high axial spatial resolution (15  $\mu\text{m}$ )<sup>61</sup> — can confirm the diagnosis of SCAD by showing the true and false lumens, intramural hematoma, dissection flaps, fenestrations, and entry tears connecting true and false lumens (Fig. 1). Intravascular imaging can also be helpful to rule out other causes of coronary-artery stenosis, including atherosclerotic plaque.

Although intravascular imaging can be a powerful diagnostic tool, procedural complications (including extension of the dissection, impaired flow after acquisition of intravascular imaging, iatrogenic dissection, and cannulation of the false lumen) have been reported in up to 8% of patients with SCAD.<sup>17</sup> Thus, intracoronary imaging is not without risk and is reserved for situations in which angiography is not diagnostic for SCAD or when intracoronary imaging is used for guidance during percutaneous coronary intervention (PCI).<sup>12,13,61</sup>

Coronary computed tomographic angiography (CCTA) can be used to visualize dissection flaps, stenoses, and intramural hematomas (which have been described as a “sleevelike” wall thickening).<sup>62</sup> CCTA is thus an attractive form of noninvasive ancillary imaging when the diagnosis of SCAD is uncertain on catheter-based angiography, particularly in cases of proximal lesions.<sup>13</sup> However, there are limitations to CCTA in the diagnosis of SCAD. Noncalcified atherosclerotic plaque can be mistaken for an intramural hematoma,<sup>63</sup> and the spatial resolution of CCTA for small vessels limits visualization of the distal portion of the vessels that is often affected by SCAD; this limited visualization can lead to false negative results.<sup>64</sup> For these reasons, catheter-based coronary angiography remains the standard when SCAD is suspected.<sup>12</sup> Finally, in some situations, SCAD is strongly suspected but angiographic findings are uncertain and ancillary imaging techniques are either not available or not diagnostic. Clinical features to support a SCAD diagnosis include coronary tortuosity on angiography,<sup>52</sup> the presence of fibromuscular dysplasia in another arterial bed,<sup>8</sup> and

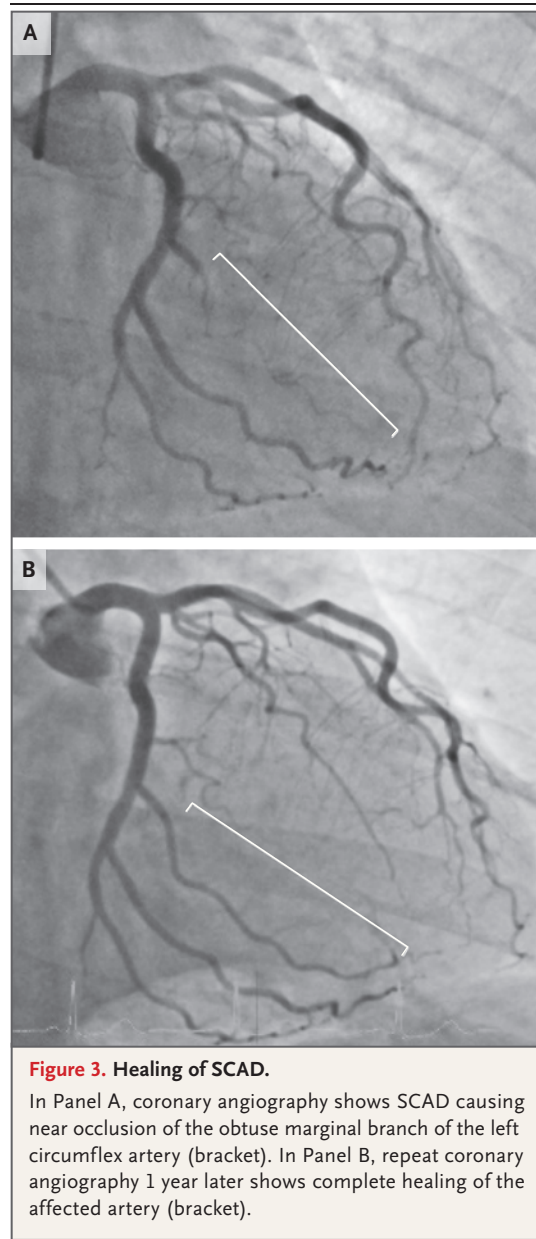
a reduction in arterial stenosis (as evidence of vessel healing) on repeat angiography.<sup>65</sup> These features should be viewed as supportive and not diagnostic because coronary tortuosity has also been associated with other entities (namely, aging and hypertension),<sup>66</sup> atherosclerosis mimicking SCAD in a patient with fibromuscular dysplasia has been reported,<sup>63</sup> and subsequent angiography does not show healing in all dissected coronary arteries.<sup>65</sup>

#### COMPREHENSIVE PATIENT CARE

##### MANAGEMENT OF ACUTE MYOCARDIAL INFARCTION

Treatment decisions with respect to acute myocardial infarction caused by SCAD are predicated on three major differences between this condition and atherosclerotic coronary lesions. First, the underlying pathophysiological feature of SCAD is medial dissection, not plaque rupture or erosion in an inflammatory and thrombotic milieu.<sup>67</sup> Second, PCI for SCAD is challenging and is associated with worse short- and long-term outcomes than those associated with PCI for atherosclerotic lesions. Finally, the majority of medically treated SCAD lesions show angiographic evidence of healing over time, with restoration of blood flow and a decrease in the severity of stenosis<sup>54,65,68</sup> (Fig. 3). For these reasons, more than 80% of patients can be successfully treated medically,<sup>4</sup> and expert consensus (not randomized trial data) suggests that medical management is preferred over immediate revascularization for patients who are in clinically stable condition.<sup>12,13</sup> Finally, because recurrent SCAD (a new SCAD event that is temporally separated from the index event)<sup>13</sup> tends to occur in different vessels from those in the initial dissection, revascularization has not been shown in long-term follow-up to prevent recurrent myocardial infarction due to SCAD.<sup>54</sup>

The decision to treat a patient who has acute myocardial infarction caused by SCAD with medical therapy or to proceed with revascularization can be complex. Factors to consider include the patient's clinical status, the territory at risk, the amount of myocardium at risk, and the degree of distal flow in the affected vessel. High-risk clinical features include persistent chest pain with evidence of ongoing or worsening ischemia, hemodynamic instability, shock, or clinically significant ventricular arrhythmias.



**Figure 3. Healing of SCAD.**

In Panel A, coronary angiography shows SCAD causing near occlusion of the obtuse marginal branch of the left circumflex artery (bracket). In Panel B, repeat coronary angiography 1 year later shows complete healing of the affected artery (bracket).

High-risk anatomical features include involvement of multivessel severe proximal dissections or of the left main artery or the ostial left anterior descending artery.<sup>12,13,69</sup> The degree of vessel flow, as determined according to the Thrombolysis in Myocardial Infarction (TIMI) grade, may also be an important indicator of whether revascularization is warranted; some experts advocate avoiding revascularization attempts if the patient is in stable condition and has adequate distal flow (TIMI grade 2 or 3) in the vessel, even if there is clinically significant stenosis.<sup>12,54,70</sup>

When high-risk features are present, consideration of immediate revascularization is warranted, with the decision to perform PCI or refer the patient for coronary-artery bypass grafting (CABG) individualized according to patient characteristics and local expertise and availability.<sup>13</sup>

PCI in patients with SCAD can be challenging for a number of reasons. Long lesions may warrant the use of multiple stents,<sup>36</sup> coronary wires can enter the false lumen and cause vessel occlusion, tortuous coronary arteries<sup>20</sup> may be prone to iatrogenic injury,<sup>71</sup> and hematoma propagation can result in the loss of distal-vessel patency or retrograde extension to more proximal vessels.<sup>72</sup> These factors contribute to PCI success rates that range from 47% to 72% in large cohort studies.<sup>4,53,54</sup> The lack of a standardized definition of procedural success in SCAD may play a role in these low reported success rates,<sup>54</sup> and SCAD-specific definitions that assign a higher importance to improvement in TIMI flow than to rapid decrease in residual stenosis may be necessary.<sup>54</sup> Possible late-term adverse events arising from the use of stents in patients with SCAD include stent malapposition as a result of resorption of intramural hematoma over time.<sup>73</sup> Large prospective studies are under way to provide data on long-term outcomes in patients who have undergone PCI for SCAD.

CABG for revascularization in patients with SCAD has been reported to be technically successful.<sup>54</sup> However, referral for this procedure is generally limited to patients with high-risk anatomical lesions (e.g., left main and multiple proximal dissections) in whom attempts at PCI have failed, in those in whom PCI is thought to be of prohibitive risk, and in those with large areas of myocardium at risk and for whom medical therapy alone is not sufficient to treat ongoing ischemia.<sup>12,13</sup> Previous studies showed a high incidence of bailout CABG after failed PCI,<sup>8,54</sup> but now fewer than 1% of patients with acute SCAD are referred for surgical revascularization overall.<sup>4</sup> Short-term success with CABG is high, but long-term patency of bypass grafts is poor<sup>54</sup> because recanalization of the native coronary arteries results in competitive flow and subsequent graft occlusion. This finding has prompted some experts to recommend the use of vein grafts to revascularize SCAD in an effort to conserve potential arterial conduits for later use should the need arise.<sup>13</sup> In a few patients

with severe illness, including cardiogenic shock and complications related to acute myocardial infarction due to SCAD, the use of advanced mechanical circulatory support with intraaortic balloon pumps, extracorporeal membrane oxygenation devices, and left ventricular assist devices has been reported as a bridge to recovery or heart transplantation.<sup>74,75</sup>

Comprehensive care for the patient with acute SCAD includes adequate inpatient monitoring to detect complications related to propagation of dissection and recurrent myocardial infarction. These complications may be manifested by recurrent or worsening anginal symptoms, new electrocardiographic changes in ischemia, a new increase in troponin levels, or new-onset ventricular arrhythmias.<sup>59,65</sup> The incidence of in-hospital recurrent myocardial infarction or unplanned revascularization is 5 to 10%,<sup>29,53</sup> and among patients who have received medical treatment, the risk of angiographically confirmed dissection extension is as high as 17% over a period of 14 days.<sup>59</sup> Coronary angiography is not without risk, but it should be considered for determination of the need for revascularization in patients with clinical deterioration.<sup>65</sup> Repeat coronary angiography, either catheter-based or CCTA, can also be considered in patients who have high-risk anatomical features with large amounts of myocardium at risk for whom revascularization is being considered before discharge.<sup>13,65</sup>

Among patients with acute myocardial infarction due to SCAD who are readmitted within 30 days after hospital discharge, 45% present with recurrent acute myocardial infarction, of whom half present within 2 days after discharge.<sup>2</sup> Although revascularization may improve flow within the dissected vessel, it does not protect against the risk of dissection extension,<sup>54</sup> and PCI may result in an increased incidence of hospital readmission at 30 days.<sup>2</sup> For these reasons, the current consensus is that hospitalization for 3 to 5 days in patients with an acute myocardial infarction due to SCAD is reasonable in order to observe for adverse ischemic events.<sup>12,13</sup>

#### MEDICAL MANAGEMENT

In addition to the management of acute myocardial infarction in patients with SCAD, the treatment objectives are to manage chronic chest pain, prevent recurrence of SCAD, assess for and



**Table 1. Long-Term Comprehensive Treatment Approach for Patients with SCAD.****Treatment Objective and Intervention****Manage chronic chest pain**

Prescribe antianginal pharmacologic therapy (e.g., nitrates, calcium-channel blockers, and ranolazine)

Perform ischemia testing

Consider diagnoses other than epicardial coronary disease

**Prevent recurrence of SCAD**

Prescribe beta-blockers

Control hypertension

Discuss guidelines for physical activity

Provide reproductive counseling

**Assess for and manage extracoronary vascular abnormalities**

Perform cross-sectional imaging with computed tomographic angiography or magnetic resonance angiography

Refer to published guidelines on the management of fibromuscular dysplasia and aneurysmal disease

**Improve quality of life**

Refer the patient for cardiac rehabilitation

Manage migraine headaches

Treat concomitant psychosocial disorders

Refer the patient to peer support groups

manage extracoronary vascular abnormalities, and improve quality of life (Table 1). Prospective clinical-trial data are lacking to guide the medical management of SCAD, and current knowledge is based on registry data and expert consensus. In addition, practitioners should consider the potential teratogenicity of medications before prescribing medications for the treatment of SCAD in women of childbearing age.

*Anticoagulation*

In accordance with guidelines for the treatment of myocardial infarction,<sup>76,77</sup> anticoagulation and dual antiplatelet therapy are often initiated before SCAD is diagnosed. The benefit and most appropriate duration of these therapies in the treatment of SCAD are unproved, and the treatment of any existing luminal thrombosis is balanced against the hypothetical risk of dissection extension due to worsening of intramural bleeding. For these reasons, in the absence of clear alternative indications, expert consensus is that anticoagulation should be discontinued after SCAD has been confirmed on angiography.<sup>12,13</sup> Given the association of thrombolysis with

clinical deterioration in patients with acute myocardial infarction due to SCAD,<sup>78</sup> the use of thrombolysis for the management of acute SCAD is not recommended.<sup>12</sup>

*Antiplatelet Therapy*

Approximately 90% of patients who have received a diagnosis of SCAD are discharged with at least one antiplatelet agent.<sup>1,4</sup> Although dual antiplatelet therapy should be administered to patients who undergo PCI,<sup>76,77</sup> evidence from clinical trials is lacking to guide the use of antiplatelet therapies in patients with SCAD. The expert consensus is that dual antiplatelet therapy may be considered during the acute phase of SCAD<sup>12</sup> and for up to 1 year for patients who receive medical treatment.<sup>13</sup> Opinions diverge with regard to the use of these agents for more than 1 year after myocardial infarction. Because quality data are lacking, the duration of antiplatelet therapy should be determined for each patient. For instance, aspirin may be considered in patients with fibromuscular dysplasia to prevent thrombotic and thromboembolic complications,<sup>42</sup> whereas a shorter duration of therapy may be warranted in premenopausal women with excess bleeding from menorrhagia who do not have other indications for antiplatelet therapy.<sup>79</sup>

*Beta-Blockers, ARBs, and ACE Inhibitors*

Major societal guidelines for the use of beta-blockers, angiotensin-receptor blockers (ARBs), and angiotensin-converting-enzyme (ACE) inhibitors in the treatment of acute myocardial infarction<sup>76,77</sup> and heart failure<sup>80</sup> should be followed for the use of these agents in patients with SCAD. Beta-blockers may have an additional benefit of preventing the recurrence of SCAD. In a single-center observational study involving 327 patients, the use of beta-blockers was associated with a 64% decrease in the incidence of recurrent SCAD over a median of 3.1 years.<sup>29</sup> Data are lacking from studies involving larger cohorts to validate the use of beta-blockers as a potential therapy to prevent the recurrence of SCAD.

*Statins*

SCAD is not mediated by atherosclerotic plaque rupture, and data are lacking to support the routine use of statins after myocardial infarction due to SCAD. Cohort studies have shown disparate results with regard to statin use for the

prevention of recurrent SCAD.<sup>29,81</sup> In the absence of firm supportive data, the use of statins may be limited to patients who otherwise meet major societal guidelines for the use of these agents in the treatment of hyperlipidemia.

#### *Antianginal Therapy*

Chest pain after SCAD is common and is a frequent cause of hospital readmissions. It accounts for 20% of readmissions within 30 days after acute myocardial infarction due to SCAD.<sup>2</sup> Chest pain may continue for several months after acute myocardial infarction even if evaluations of ischemia are normal or repeat coronary imaging shows vessel healing.<sup>82,83</sup> Chest pain in patients with abnormal ischemia testing should be treated with medical therapy and investigated with further cardiac testing. However, coronary vasospasm, endothelial dysfunction, microvascular disease, catamenial chest pain,<sup>82</sup> and noncardiac chest pain should be considered in patients who continue to have atypical chest pain that is not associated with abnormal ischemia testing.<sup>13</sup> Nitrates, calcium-channel blockers, and ranolazine are potential therapies to consider.<sup>13</sup>

#### **PREVENTION OF SCAD RECURRENCE**

Mortality after SCAD is low — 1% over a period of 3 years<sup>29</sup> to 2% over a period of 1 year.<sup>5</sup> In contrast, the incidence of recurrent myocardial infarction is substantial, with 17 to 18%<sup>29,81</sup> of patients having recurrent myocardial infarction over a span of 3 to 4 years. The majority of these recurrent myocardial infarctions are due to recurrent SCAD. Recurrent SCAD is defined as a new dissection event that is temporally separated from the index SCAD event, usually in a different coronary artery.<sup>13</sup> It is pathophysiologically distinct from SCAD extension, the expansion of a known area of intramural hematoma causing clinical worsening or repeated elevation in cardiac enzyme levels during the acute phase of SCAD. Rates of recurrence have ranged from 5% over a median of 22 months<sup>53</sup> to 15% over a median of 27 months.<sup>54</sup> Factors associated with SCAD recurrence are a history of hypertension,<sup>29</sup> fibromuscular dysplasia,<sup>5</sup> migraine headaches,<sup>5</sup> and coronary-artery tortuosity.<sup>20</sup> Given the potential benefit of beta-blockers in preventing recurrence,<sup>29</sup> preferential prescription of beta-blockers could be considered for the treatment of hypertension in patients with SCAD.

Strenuous physical activity has been associated with SCAD, but firm supportive data are lacking to establish proscriptive limits on heart rate during exercise or the amount of weight that can be lifted to prevent the recurrence of SCAD. Although the safety of lower limits of target heart rate, systolic blood pressure, and weights for resistance exercise training were defined in a SCAD-specific cardiac rehabilitation program,<sup>83</sup> activity guidelines should be tailored to the physical fitness of the individual patient, and other factors should be considered, including the presence of concomitant arteriopathies.<sup>13</sup> Patients are advised to avoid isometric exercise, high-intensity endurance training, exercising to the point of exhaustion, and activities that involve a prolonged Valsalva maneuver.<sup>12,13</sup>

Data to determine whether pregnancy is a risk factor for recurrence of SCAD are lacking. SCAD recurrence with pregnancy has been reported in case series form only.<sup>84,85</sup> Because SCAD is a prevalent cause of myocardial infarction during pregnancy and pregnancy-associated SCAD has been shown to have severe manifestations, women who have had SCAD and who wish to become pregnant should receive preconception counseling. If pregnancy has already occurred, a multidisciplinary approach to care for the high-risk cardiac patient should be adopted.<sup>12,13</sup>

#### **ASSESSMENT AND MANAGEMENT OF EXTRACORONARY VASCULAR ABNORMALITIES**

Studies showing a long-term benefit of extracoronary vascular imaging after a SCAD diagnosis are lacking. However, because the prevalence of coexisting arterial abnormalities outside the heart among patients with SCAD is high, axial imaging from the head to pelvis with dedicated computed tomographic angiography or magnetic resonance angiography is recommended.<sup>12,13,42</sup> The yield and benefit of periodically repeating vascular imaging with axial imaging are unknown. Surveillance and treatment of fibromuscular dysplasia and aneurysmal disease should be performed according to published guidelines.<sup>42,86,87</sup>

#### **IMPROVEMENT IN QUALITY OF LIFE**

Migraine headaches,<sup>22</sup> anxiety, depression, and post-traumatic stress disorder that commonly occur in patients after SCAD have a considerable effect on patients' quality of life.<sup>88</sup> Appropriate screening, treatment, and referral for these con-

ditions are recommended.<sup>13,89</sup> Similarly, cardiac rehabilitation is safe<sup>83,90</sup> and may improve perceived emotional well-being<sup>91</sup> and decrease depression, stress,<sup>90</sup> and symptoms of chest pain.<sup>83</sup> Cardiac rehabilitation is recommended for all patients with myocardial infarction due to SCAD.<sup>13</sup> Finally, patients may be referred to patient organizations<sup>92-94</sup> and peer online communities for support, education, and information about the opportunity to participate in clinical research.

## CONCLUSIONS

SCAD, an important cause of acute myocardial infarction, disproportionately affects women and

is an entity that is pathophysiologically distinct from atherosclerotic myocardial infarction. Medical management is preferred over attempts at revascularization. SCAD may be a first manifestation of an underlying systemic arteriopathy, and the diagnosis and treatment of extracoronary vascular abnormalities are important components in the comprehensive care of patients with SCAD. Care also includes measures to prevent the recurrence of SCAD and improve the patient's quality of life.

Dr. Kim reports receiving advisory board fees from Acer Therapeutics. No other potential conflict of interest relevant to this article was reported.

Disclosure forms provided by the author are available at NEJM.org.

## REFERENCES

- García-Guimaraes M, Bastante T, Macaya F, et al. Spontaneous coronary artery dissection in Spain: clinical and angiographic characteristics, management, and in-hospital events. *Rev Esp Cardiol (Engl Ed)* 2020 May 14 (Epub ahead of print).
- Gad MM, Mahmoud AN, Saad AM, et al. Incidence, clinical presentation, and causes of 30-day readmission following hospitalization with spontaneous coronary artery dissection. *JACC Cardiovasc Interv* 2020;13:921-32.
- Sharma S, Kaadan MI, Duran JM, et al. Risk factors, imaging findings, and sex differences in spontaneous coronary artery dissection. *Am J Cardiol* 2019;123:1783-7.
- Saw J, Starovoytov A, Humphries K, et al. Canadian spontaneous coronary artery dissection cohort study: in-hospital and 30-day outcomes. *Eur Heart J* 2019;40:1188-97.
- Clare R, Duan L, Phan D, et al. Characteristics and clinical outcomes of patients with spontaneous coronary artery dissection. *J Am Heart Assoc* 2019;8(10):e012570.
- Kim ESH, Tweet MS. Spontaneous coronary artery dissection: a call for consensus and research advancement. *J Am Coll Cardiol* 2019;74:1301-3.
- Kaadan MI, MacDonald C, Ponzini F, et al. Prospective cardiovascular genetics evaluation in spontaneous coronary artery dissection. *Circ Genom Precis Med* 2018;11(4):e001933.
- Saw J, Aymong E, Sedlak T, et al. Spontaneous coronary artery dissection: association with predisposing arteriopathies and precipitating stressors and cardiovascular outcomes. *Circ Cardiovasc Interv* 2014;7:645-55.
- Prasad M, Tweet MS, Hayes SN, et al. Prevalence of extracoronary vascular abnormalities and fibromuscular dysplasia in patients with spontaneous coronary artery dissection. *Am J Cardiol* 2015;115:1672-7.
- Basso C, Morgagni GL, Thiene G. Spontaneous coronary artery dissection: a neglected cause of acute myocardial ischaemia and sudden death. *Heart* 1996;75:451-4.
- Vrints CJM. Spontaneous coronary artery dissection. *Heart* 2010;96:801-8.
- Adlam D, Alfonso F, Maas A, Vrints C. European Society of Cardiology, Acute Cardiovascular Care Association, SCAD Study Group: a position paper on spontaneous coronary artery dissection. *Eur Heart J* 2018;39:3353-68.
- Hayes SN, Kim ESH, Saw J, et al. Spontaneous coronary artery dissection: current state of the science: a scientific statement from the American Heart Association. *Circulation* 2018;137(19):e523-e557.
- Kearney P, Erbel R, Ge J, et al. Assessment of spontaneous coronary artery dissection by intravascular ultrasound in a patient with unstable angina. *Cathet Cardiovasc Diagn* 1994;32:58-61.
- Aqel RA, Zoghbi GJ, Iskandrian AE. Spontaneous coronary artery dissection with pseudoaneurysm formation diagnosed by intravascular ultrasound: a case report. *Echocardiography* 2004;21:153-7.
- Maehara A, Mintz GS, Castagna MT, et al. Intravascular ultrasound assessment of spontaneous coronary artery dissection. *Am J Cardiol* 2002;89:466-8.
- Jackson R, Al-Hussaini A, Joseph S, et al. Spontaneous coronary artery dissection: pathophysiological insights from optical coherence tomography. *JACC Cardiovasc Imaging* 2019;12:2475-88.
- Saw J, Mancini GBJ, Humphries K, et al. Angiographic appearance of spontaneous coronary artery dissection with intramural hematoma proven on intracoronary imaging. *Catheter Cardiovasc Interv* 2016;87(2):E54-E61.
- Saw J. Coronary angiogram classification of spontaneous coronary artery dissection. *Catheter Cardiovasc Interv* 2014;84:1115-22.
- Eleid MF, Guddeti RR, Tweet MS, et al. Coronary artery tortuosity in spontaneous coronary artery dissection: angiographic characteristics and clinical implications. *Circ Cardiovasc Interv* 2014;7:656-62.
- Al-Hussaini A, Adlam D. Spontaneous coronary artery dissection. *Heart* 2017;103:1043-51.
- Kok SN, Hayes SN, Cutrer FM, et al. Prevalence and clinical factors of migraine in patients with spontaneous coronary artery dissection. *J Am Heart Assoc* 2018;7(24):e010140.
- Mahmoud AN, Taduru SS, Mentias A, et al. Trends of incidence, clinical presentation, and in-hospital mortality among women with acute myocardial infarction with or without spontaneous coronary artery dissection: a population-based analysis. *JACC Cardiovasc Interv* 2018;11:80-90.
- Saw J, Aymong E, Mancini GB, Sedlak T, Starovoytov A, Rjcci D. Nonatherosclerotic coronary artery disease in young women. *Can J Cardiol* 2014;30:814-9.
- Nakashima T, Noguchi T, Haruta S, et al. Prognostic impact of spontaneous coronary artery dissection in young female patients with acute myocardial infarction: a report from the Angina Pectoris-Myocardial Infarction Multicenter Investigators in Japan. *Int J Cardiol* 2016;207:341-8.
- Faden MS, Bottega N, Benjamin A, Brown RN. A nationwide evaluation of spontaneous coronary artery dissection in pregnancy and the puerperium. *Heart* 2016;102:1974-9.
- Smilowitz NR, Gupta N, Guo Y, et al.

- Acute myocardial infarction during pregnancy and the puerperium in the United States. *Mayo Clin Proc* 2018;93:1404-14.
28. Fahmy P, Prakash R, Starovoytov A, Boone R, Saw J. Pre-disposing and precipitating factors in men with spontaneous coronary artery dissection. *JACC Cardiovasc Interv* 2016;9:866-8.
  29. Saw J, Humphries K, Aymong E, et al. Spontaneous coronary artery dissection: clinical outcomes and risk of recurrence. *J Am Coll Cardiol* 2017;70:1148-58.
  30. Robinowitz M, Virmani R, McAllister HA Jr. Spontaneous coronary artery dissection and eosinophilic inflammation: a cause and effect relationship? *Am J Med* 1982;72:923-8.
  31. Kajihara H, Tachiyama Y, Hirose T, et al. Eosinophilic coronary periarteritis (vasospastic angina and sudden death), a new type of coronary arteritis: report of seven autopsy cases and a review of the literature. *Virchows Arch* 2013;462:239-48.
  32. Lunebourg A, Letovanec I, Eggenberger P, Lehr HA. Images in cardiovascular medicine. Sudden cardiac death due to triple vessel coronary dissection. *Circulation* 2008;117:2038-40.
  33. D'Ovidio C, Sablone S, Carnevale A. Spontaneous coronary artery dissection: case report and literature review. *J Forensic Sci* 2015;60:801-6.
  34. Makino Y, Inokuchi G, Yokota H, et al. Sudden death due to coronary artery dissection associated with fibromuscular dysplasia revealed by postmortem selective computed tomography coronary angiography: a case report. *J Forensic Sci* 2015;253:e10-e15.
  35. Moulson N, Kelly J, Iqbal MB, Saw J. Histopathology of coronary fibromuscular dysplasia causing spontaneous coronary artery dissection. *JACC Cardiovasc Interv* 2018;11:909-10.
  36. Lobo AS, Cantu SM, Sharkey SW, et al. Revascularization in patients with spontaneous coronary artery dissection and ST-segment elevation myocardial infarction. *J Am Coll Cardiol* 2019;74:1290-300.
  37. Tweet MS, Hayes SN, Codsí E, Gulati R, Rose CH, Best PJM. Spontaneous coronary artery dissection associated with pregnancy. *J Am Coll Cardiol* 2017;70:426-35.
  38. Havakuk O, Goland S, Mehra A, Elkayam U. Pregnancy and the risk of spontaneous coronary artery dissection: an analysis of 120 contemporary cases. *Circ Cardiovasc Interv* 2017;10:e004941-e004941.
  39. Goel K, Tweet M, Olson TM, Maleszewski JJ, Gulati R, Hayes SN. Familial spontaneous coronary artery dissection: evidence for genetic susceptibility. *JAMA Intern Med* 2015;175:821-6.
  40. Henkin S, Negrotto SM, Tweet MS, et al. Spontaneous coronary artery dissection and its association with heritable connective tissue disorders. *Heart* 2016;102:876-81.
  41. Verstraeten A, Perik MHAM, Baranowska AA, et al. Enrichment of rare variants in Loeys-Dietz syndrome genes in spontaneous coronary artery dissection but not in severe fibromuscular dysplasia. *Circulation* 2020;142:1021-4.
  42. Gornik HL, Persu A, Adlam D, et al. First International Consensus on the diagnosis and management of fibromuscular dysplasia. *Vasc Med* 2019;24:164-89.
  43. Adlam D, Olson TM, Combaret N, et al. Association of the PHACTR1/EDN1 genetic locus with spontaneous coronary artery dissection. *J Am Coll Cardiol* 2019;73:58-66.
  44. Turley TN, O'Byrne MM, Kosel ML, et al. Identification of susceptibility loci for spontaneous coronary artery dissection. *JAMA Cardiol* 2020;5:929-38.
  45. Saw J, Yang M-L, Trinder M, et al. Chromosome 1q21.2 and additional loci influence risk of spontaneous coronary artery dissection and myocardial infarction. *Nat Commun* 2020;11:4432.
  46. Fahey JK, Williams SM, Tyagi S, et al. The intercellular tight junction and spontaneous coronary artery dissection. *J Am Coll Cardiol* 2018;72:1752-3.
  47. Turley TN, Theis JL, Sundsbak RS, et al. Rare missense variants in TLN1 are associated with familial and sporadic spontaneous coronary artery dissection. *Circ Genom Precis Med* 2019;12(4):e002437.
  48. Sun Y, Chen Y, Li Y, et al. Association of TSR1 variants and spontaneous coronary artery dissection. *J Am Coll Cardiol* 2019;74:167-76.
  49. Georges A, Albuissou J, Berrandou T, et al. Rare loss-of-function mutations of PTGIR are enriched in fibromuscular dysplasia. *Cardiovasc Res* 2020 June 12 (Epub ahead of print).
  50. Lie JT, Berg KK. Isolated fibromuscular dysplasia of the coronary arteries with spontaneous dissection and myocardial infarction. *Hum Pathol* 1987;18:654-6.
  51. Hill LD, Antonius JJ. Arterial dysplasia: an important surgical lesion. *Arch Surg* 1965;90:585-95.
  52. Saw J, Bezerra H, Gornik HL, Machan L, Mancini GB. Angiographic and intracoronary manifestations of coronary fibromuscular dysplasia. *Circulation* 2016;133:1548-59.
  53. Lettieri C, Zavalloni D, Rossini R, et al. Management and long-term prognosis of spontaneous coronary artery dissection. *Am J Cardiol* 2015;116:66-73.
  54. Tweet MS, Eleid MF, Best PJ, et al. Spontaneous coronary artery dissection: revascularization versus conservative therapy. *Circ Cardiovasc Interv* 2014;7:777-86.
  55. Phan D, Clare R, Duan L, Kim C, Moore N, Lee MS. Characteristics and outcomes of patients with spontaneous coronary artery dissection who suffered sudden cardiac arrest. *J Interv Card Electrophysiol* 2020 February 11 (Epub ahead of print).
  56. Cheung CC, Starovoytov A, Parsa A, et al. In-hospital and long-term outcomes among patients with spontaneous coronary artery dissection presenting with ventricular tachycardia/fibrillation. *Heart Rhythm* 2020;17:1864-9.
  57. Luong C, Starovoytov A, Heydari M, Sedlak T, Aymong E, Saw J. Clinical presentation of patients with spontaneous coronary artery dissection. *Catheter Cardiovasc Interv* 2017;89:1149-54.
  58. Lindor RA, Tweet MS, Goyal KA, et al. Emergency department presentation of patients with spontaneous coronary artery dissection. *J Emerg Med* 2017;52:286-91.
  59. Waterbury TM, Tweet MS, Hayes SN, et al. Early natural history of spontaneous coronary artery dissection. *Circ Cardiovasc Interv* 2018;11(9):e006772.
  60. Arnold JR, West NE, van Gaal WJ, Karamitsos TD, Banning AP. The role of intravascular ultrasound in the management of spontaneous coronary artery dissection. *Cardiovasc Ultrasound* 2008;6:24.
  61. Alfonso F, Paulo M, Gonzalo N, et al. Diagnosis of spontaneous coronary artery dissection by optical coherence tomography. *J Am Coll Cardiol* 2012;59:1073-9.
  62. Pozo-Osinalde E, García-Guimaraes M, Bastante T, et al. Characteristic findings of acute spontaneous coronary artery dissection by cardiac computed tomography. *Coron Artery Dis* 2020;31:293-9.
  63. Tweet MS, Akhtar NJ, Hayes SN, Best PJ, Gulati R, Araoz PA. Spontaneous coronary artery dissection: acute findings on coronary computed tomography angiography. *Eur Heart J Acute Cardiovasc Care* 2019;8:467-75.
  64. Eleid MF, Tweet MS, Young PM, Williamson E, Hayes SN, Gulati R. Spontaneous coronary artery dissection: challenges of coronary computed tomography angiography. *Eur Heart J Acute Cardiovasc Care* 2018;7:609-13.
  65. Hassan S, Prakash R, Starovoytov A, Saw J. Natural history of spontaneous coronary artery dissection with spontaneous angiographic healing. *JACC Cardiovasc Interv* 2019;12:518-27.
  66. Kahe F, Sharfaei S, Pitliya A, et al. Coronary artery tortuosity: a narrative review. *Coron Artery Dis* 2020;31:187-92.
  67. Crea F, Libby P. Acute coronary syndromes: the way forward from mechanisms to precision treatment. *Circulation* 2017;136:1155-66.
  68. Rogowski S, Maeder MT, Weilenmann D, et al. Spontaneous coronary artery dissection: angiographic follow-up and long-term clinical outcome in a predominantly medically treated population. *Catheter Cardiovasc Interv* 2017;89:59-68.
  69. Saw J, Mancini GBJ, Humphries KH. Contemporary review on spontaneous

- coronary artery dissection. *J Am Coll Cardiol* 2016;68:297-312.
70. Tweet MS, Gulati R, Williamson EE, Vrtiska TJ, Hayes SN. Multimodality imaging for spontaneous coronary artery dissection in women. *JACC Cardiovasc Imaging* 2016;9:436-50.
71. Prakash R, Starovoytov A, Heydari M, Mancini GB, Saw J. Catheter-induced iatrogenic coronary artery dissection in patients with spontaneous coronary artery dissection. *JACC Cardiovasc Interv* 2016; 9:1851-3.
72. Conrotto F, D'Ascenzo F, Cerrato E, et al. Safety and efficacy of drug eluting stents in patients with spontaneous coronary artery dissection. *Int J Cardiol* 2017; 238:105-9.
73. Lempereur M, Fung A, Saw J. Stent mal-apposition with resorption of intramural hematoma with spontaneous coronary artery dissection. *Cardiovasc Diagn Ther* 2015;5:323-9.
74. Cox J, Roberts WC, Araj FG, et al. Acute isolated coronary artery dissection causing massive acute myocardial infarction and leading to unsuccessful coronary bypass, extracorporeal life support, and successful cardiac transplantation. *Am J Cardiol* 2020;125:1446-8.
75. Sharma S, Polak S, George Z, et al. Management of spontaneous coronary artery dissection complicated by cardiogenic shock using mechanical circulatory support with the Impella device. *Catheter Cardiovasc Interv* 2019 December 26 (Epub ahead of print).
76. Amsterdam EA, Wenger NK, Brindis RG, et al. 2014 AHA/ACC guideline for the management of patients with non-ST-elevation acute coronary syndromes: a report of the American College of Cardiology/American Heart Association Task Force on Practice Guidelines. *J Am Coll Cardiol* 2014;64(24):e139-e228.
77. O'Gara PT, Kushner FG, Ascheim DD, et al. 2013 ACCF/AHA guideline for the management of ST-elevation myocardial infarction: a report of the American College of Cardiology Foundation/American Heart Association Task Force on Practice Guidelines. *J Am Coll Cardiol* 2013;61(4): e78-e140.
78. Shamloo BK, Chintala RS, Nasur A, et al. Spontaneous coronary artery dissection: aggressive vs. conservative therapy. *J Invasive Cardiol* 2010;22:222-8.
79. Maas AHEM, Euler M, Bongers MY, et al. Practice points in gynecardiology: abnormal uterine bleeding in premenopausal women taking oral anticoagulant or antiplatelet therapy. *Maturitas* 2015;82: 355-9.
80. Yancy CW, Jessup M, Bozkurt B, et al. 2017 ACC/AHA/HFSA focused update of the 2013 ACCF/AHA guideline for the management of heart failure: a report of the American College of Cardiology/American Heart Association Task Force on Clinical Practice Guidelines and the Heart Failure Society of America. *J Card Fail* 2017;23:628-51.
81. Tweet MS, Hayes SN, Pitta SR, et al. Clinical features, management, and prognosis of spontaneous coronary artery dissection. *Circulation* 2012;126:579-88.
82. Tweet MS, Codsí E, Best PJM, Gulati R, Rose CH, Hayes SN. Menstrual chest pain in women with history of spontaneous coronary artery dissection. *J Am Coll Cardiol* 2017;70:2308-9.
83. Chou AY, Prakash R, Rajala J, et al. The first dedicated cardiac rehabilitation program for patients with spontaneous coronary artery dissection: description and initial results. *Can J Cardiol* 2016;32: 554-60.
84. Tweet MS, Young KA, Best PJM, et al. Association of pregnancy with recurrence of spontaneous coronary artery dissection among women with prior coronary artery dissection. *JAMA Netw Open* 2020; 3(9):e2018170.
85. Tweet MS, Hayes SN, Gulati R, Rose CH, Best PJ. Pregnancy after spontaneous coronary artery dissection: a case series. *Ann Intern Med* 2015;162:598-600.
86. Chaer RA, Abularrage CJ, Coleman DM, et al. The Society for Vascular Surgery clinical practice guidelines on the management of visceral aneurysms. *J Vasc Surg* 2020;72:1S:3S-39S.
87. Etminan N, Brown RD Jr, Beseoglu K, et al. The unruptured intracranial aneurysm treatment score: a multidisciplinary consensus. *Neurology* 2015;85:881-9.
88. Johnson AK, Hayes SN, Sawchuk C, et al. Analysis of posttraumatic stress disorder, depression, anxiety, and resiliency within the unique population of spontaneous coronary artery dissection survivors. *J Am Heart Assoc* 2020;9(9):e014372.
89. Lichtman JH, Bigger JT Jr, Blumenthal JA, et al. Depression and coronary heart disease: recommendations for screening, referral, and treatment: a science advisory from the American Heart Association Prevention Committee of the Council on Cardiovascular Nursing, Council on Clinical Cardiology, Council on Epidemiology and Prevention, and Interdisciplinary Council on Quality of Care and Outcomes Research: endorsed by the American Psychiatric Association. *Circulation* 2008; 118:1768-75.
90. Silber TC, Tweet MS, Bowman MJ, Hayes SN, Squires RW. Cardiac rehabilitation after spontaneous coronary artery dissection. *J Cardiopulm Rehabil Prev* 2015;35:328-33.
91. Krittanawong C, Tweet MS, Hayes SE, et al. Usefulness of cardiac rehabilitation after spontaneous coronary artery dissection. *Am J Cardiol* 2016;117:1604-9.
92. SCAD Alliance home page ([www.scadalliance.org](http://www.scadalliance.org)).
93. Beat SCAD home page ([www.beatscad.org.uk](http://www.beatscad.org.uk)).
94. SCAD Research home page ([www.scadresearch.org](http://www.scadresearch.org)).

Copyright © 2020 Massachusetts Medical Society.